



PATIENT

Diesel Bailey

PRESENTING CLINICAL SIGNS

History: Grade II/VI heart murmur; no clinical signs. BP: 140-150mmHg.

SPECIES

Canine

ECHOCARDIOGRAM FINDINGS

2D, m-mode, color flow and Doppler imaging is available.

Left ventricle: The LV diameter is normal with adequate myocardial function. LV wall thicknesses are normal.

BREED

Pitbull

Left atrium: The left atrium is normal in dimension.

Mitral valve: The mitral valve is normal with no prolapse into the left atrial lumen. No mitral regurgitation.

SEX

Male Neutered

Aortic valve/aorta: The aortic valve is normal in morphology and mobility. Mildly elevated aortic outflow velocity; laminar flow. No aortic insufficiency.

Right ventricle: Normal right ventricular diameter and morphology indicating no overt evidence of pulmonary arterial hypertension.

AGE

5 years

Right atrium: Normal RA dimension.

Tricuspid valve: The tricuspid valve appears normal with trace tricuspid regurgitation. Normal velocity.

WEIGHT

8.3lbs

Pulmonic valve/pulmonary artery: The pulmonic valve is normal in morphology and mobility. No pulmonic insufficiency. Normal RVOT velocity; laminar flow.

Pericardium/other: No pericardial or pleural effusion noted. No obvious cardiac masses.

Heart rhythm: ECG reveals a sinus rhythm with an average HR of 150bpm.

2-Dimensional Measurements

Ao diam (cm)	2.5
LA diam (cm)	2.7
LA:Ao (Swe)	1.1
IVS thickness (cm)	1.0
LVID diastole (cm)	3.8
PW thickness (cm)	1.1
LVID systole (cm)	2.5
FS (%)	35

Doppler Measurements

PV Vmax (m/s)	0.9
AoV Vmax (m/s)	2.1
MR Vmax (m/s)	NA
TR Vmax (m/s)	2.2
TR PG (mmHg)	20

INTERPRETED BY

Maggie Machen
Lamy, DVM
DACVIM (Cardiology)

IMAGING

PERFORMED BY

Pamela Harrigan,
RDCS

INTERPRETATION OF THE FINDINGS

The only cause of a murmur identified is increased flow velocity through the LVOT/aortic root. No obvious subaortic ridge or valvular abnormalities are visualized, and in the absence of structural abnormalities this is considered a benign flow murmur. If this is a new murmur, it is reasonable to monitor periodically via recheck echocardiography in the future. Additionally, screening for fluid status abnormalities (dehydration, anemia, etc.) is recommended through routine lab work as these abnormalities would make this finding more prevalent. No significant valvular insufficiencies were noted, and no structural issues identified.

HOSPITAL NAME

Wignall Animal
Hospital

REFERRING VET

Dr. Thomas

Prognosis is good.

INVOICE

23819

DATE

4/21/22



PATIENT

Diesel Bailey

SPECIES

Canine

BREED

Pitbull

SEX

Male Neutered

AGE

5 years

WEIGHT

8.3lbs

INTERPRETED BY

Maggie Machen
Lamy, DVM
DACVIM (Cardiology)

**IMAGING
PERFORMED BY**

Pamela Harrigan,
RDCS

HOSPITAL NAME

Wignall Animal
Hospital

REFERRING VET

Dr. Thomas

INVOICE

23819

DATE

4/21/22

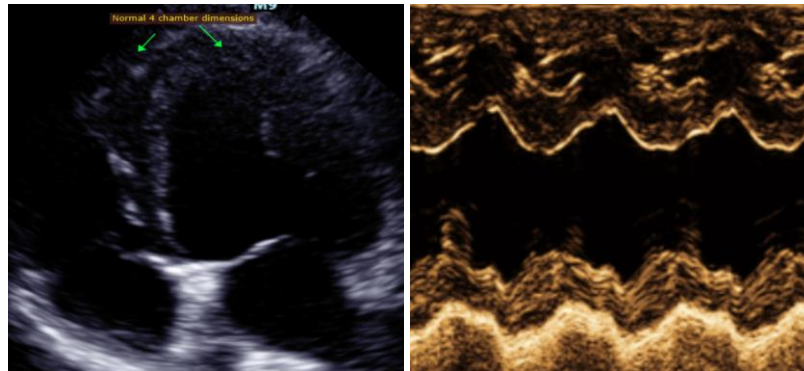
RECOMMENDATIONS

- No cardiac medications are indicated.
- Baseline lab work recommended if not recently performed.
- No cardiac contraindication for general anesthesia.
- Monitor for development of a cough, labored breathing, exercise intolerance or collapse episodes.

PLAN

Recommend recheck echocardiogram in 12-18 months to screen for progression or development of concurrent cardiac disease that the preexisting murmur may mask.

IMAGES



The information and recommendations provided are based on the images presented by the referring veterinarian. No evaluation can be communicated regarding pathology that was not visible in the image/video clips provided.

Thank you for this referral. This report was generated using transcription software, and minor dictation errors may be present. If the clinical or image interpretation does not parallel your findings or if I can be of any further assistance, please contact me.

Maggie Machen Lamy, DVM
Diplomate of the American College of Veterinary Internal Medicine (Cardiology)
info@sonopath.com